

MANAGING RECURRENT URINARY TRACT INFECTIONS IN PRIMARY CARE — CAN WE DO BETTER?

Dr Ong Hui Li Julia, A/P Goh Lee Gan

ABSTRACT

A middle-aged lady was treated and followed up for recurrent urinary tract infections (UTI) with increasingly resistant organisms without documentation of interval resolution of infection by negative urine cultures. We discuss the events following the diagnosis of her fourth urinary tract infection. Referral for further evaluation of her urinary tract in view of recurrent UTI showed she had a bladder cancer. The investigation and management of recurrent UTI is reviewed. The link between bladder cancer and recurrent urinary tract infection is also explored.

Keywords: Recurrent Urinary Tract Infections; Bladder Cancer;

SFP2017; 43(2): 39-42

PATIENT'S REVELATION

"I've had this problem before, could you give me some antibiotics?"

The Patient's Presenting Complaint

Madam (Mdm) W was first seen at the polyclinic in October 2014. She is a 56-year-old homemaker. She complained of dysuria, urgency, urge incontinence and a low-grade fever for 1 week. She did not have a history of diabetes, smoking, or any long-term medication. She had been postmenopausal for 3 years. Immediately following her symptom review came the question, "I've had this problem before, could you give me some antibiotics?"

She described episodes of similar symptoms in the past 2 years occurring once every 2 months which she brought to medical attention thrice. She did not consult a physician at every visit as the symptoms were too common and she associated it with the onset of menopause. At each episode, the resolution of symptoms after antibiotics were taken as clearance of infection and there was no documented negative urine culture. Mdm W mentioned that doctors told her that urinary tract infections were common in ladies and no doctor had mentioned the need for a repeat urine culture post antibiotic course before.

Physical Findings When First Seen in October 2014

On examination, the patient was afebrile and comfortable. Her abdomen was soft with no suprapubic tenderness or masses, and the renal punch was negative bilaterally. On inspection of her perineum, there was no cystocele on coughing and the vaginal walls were atrophic. On microscopic examination, her urine was pyuric at 25 white blood cells/ μ L with no microscopic haematuria.

GAINING INSIGHT: WHAT ARE THE ISSUES?

This case highlighted a few issues:

1. Are the recurrent UTIs new infections or incompletely treated infections resulting in relapse of infection?
2. Should a referral to a urologist have been done?

New Infection or Relapse to Explain the Recurrent Episodes?

There was no record that the urine infection was followed up with repeat cultures to establish cure. Hence, the situation remained unclear. A search of the literature showed that in the follow-up for recurrent UTI, a urine and sensitivity analysis should be recommended when the patient is symptomatic. This should be repeated 2 weeks from the sensitivity-adjusted treatment, in order to confirm UTI, guide further treatment and exclude persistence (Level 4 evidence, Grade C recommendation).¹

Should a Referral to a Urologist be Done?

As the latest infection when seen in October 2014 was a fourth infection, the indication for referral was thought necessary. The literature review showed it to be best practice to investigate with a CT urogram or abdominopelvic ultrasound +/- abdominal X-ray should there be a suspicion of a complicated UTI in a patient without a known urological abnormality.¹

STUDY THE MANAGEMENT: HOW DO WE APPLY THE ANSWERS TO THE ISSUES RAISED IN THIS PATIENT IN OUR CLINICAL PRACTICE?

Treating this Infection

Which antibiotic should be used in a recurrent infection?

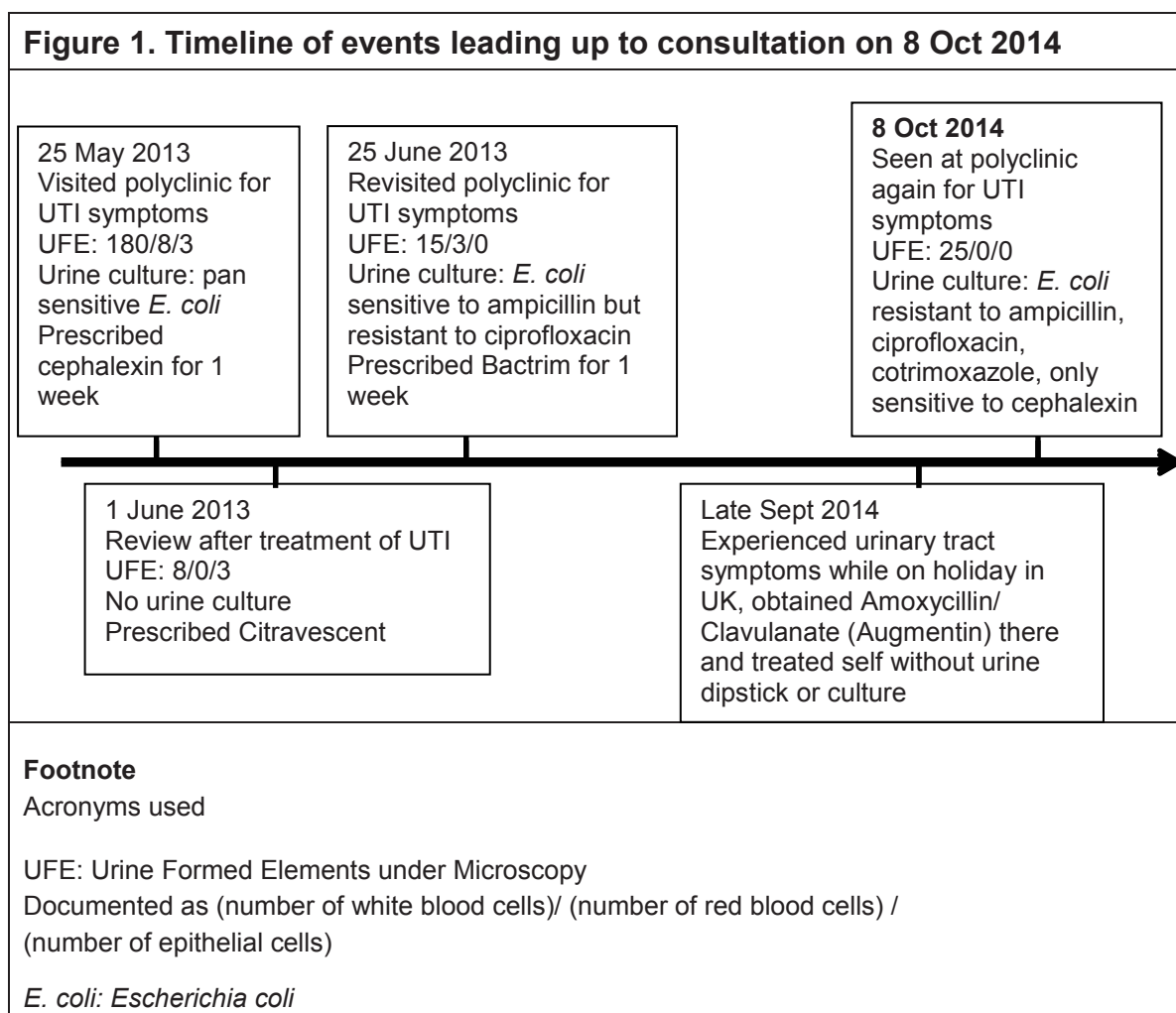
Reviewing Mdm W's history of urine cultures, it was found that the Escherichia Coli (E. coli) was the cultured organism in three of the 4 infections (see Figure 1). As the antibiotic to which the E coli in the June 2013 infection was sensitive to was Ampicillin, a urine culture was sent off and she was empirically

ONG HUI LI JULIA

Chief Resident, Family Medicine Residency Program
National University Health System

GOH LEE GAN

Professorial Fellow
Division of Family Medicine
National University Health System

Figure 1. Timeline of events leading up to consultation on 8 Oct 2014

prescribed a week's course of oral Augmentin.

How can we prevent recurrence?

Non-pharmacological advice such as micturating after intercourse and wiping the perineal area from front to back was given. A follow-up appointment 2 weeks later was planned for to review symptoms and to perform a repeat urine culture to document clearance of bacteria.

The Culture Results

Prior to the 2-week appointment, her urine culture results returned growing *E. coli* that was now resistant to Ampicillin, Ciprofloxacin and Cotrimoxazole. Mdm W was called back to the polyclinic to collect a course of Cephalexin instead and to complete it without missing doses.

REFERRAL

The patient was reviewed 2 weeks after the antibiotic course by myself and symptoms had resolved then. Without prior documented bacterial clearance and increasing antibiotic resistance, a presumption of unresolved cystitis was made and there was a concern regarding an underlying structural abnormality. Thus, a specialist referral was made.

FURTHER INVESTIGATIONS AND MANAGEMENT

Imaging and Diagnosis

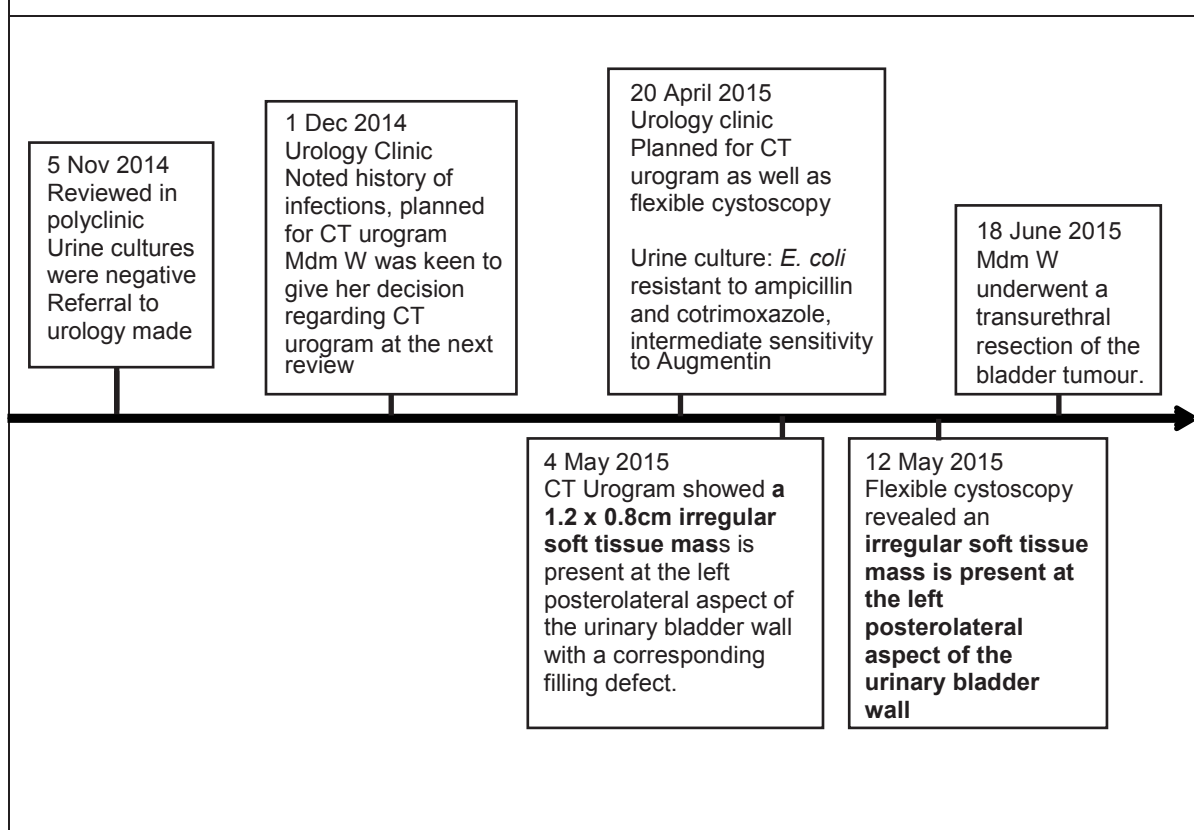
The Computer Tomographic (CT) urogram organised by the urologist revealed a 1.2 x 0.8cm irregular soft tissue mass at the left posterolateral aspect of the urinary bladder wall with a corresponding filling defect in the delayed phase of contrast washout (Figure 1). Flexible cystoscopy done May 2015 showed a papillary bladder tumour on the bladder wall (Figure 2).

Bladder Resection

Mdm W underwent a transurethral resection of the bladder tumour on 18/6/15 and a single 0.6cm papillary left posterolateral wall bladder tumour was found intraoperatively. Histology reports post resection showed a low-grade, non-invasive papillary urothelial cell carcinoma with no evidence of stromal or muscle invasion.

Post operation progress

A phone call to Mdm W was made after her surgery and she expressed relief that it was a curable tumour and that it had been brought to a specialist's attention for appropriate

Figure 2. Timeline of Events after Referral

investigation. She remained well post-surgery with continued urological follow up.

DISCUSSION

Understanding Recurrent UTIs

Mdm W had recurrent urinary tract infections, defined as 2 uncomplicated infections in a 6-month period or 3 infections within a year. A relapse UTI is caused by the same bacterial strain implicated in a previous UTI within 2 weeks of the completion of treatment for the original infection, while a reinfection is a UTI arising more than 2 weeks after treatment or after sterile intervening culture, even if the infecting pathogen is the same as the original.²

Gaps in Management of this Case

There was a lack of documented treatment success with a negative urine culture from the first presentation with UTI symptoms in June 2013 till she reached the urology clinic in December 2014. Instead, she had 4 positive urine cultures growing *E. coli* with increasing resistance. The shortfall in the management included a lack of UTI clearance as well as lack of communication between her general practitioner and the various doctors who saw her in the polyclinic.

Suggested Improvements

Communication between family physicians could be

improved, for instance with a note in the plan for “referral to urology if repeat visit for UTI”, particularly for centres with no guarantee that the same doctor will manage the patient at other acute visits. Educating the patient regarding the importance of a documented clearance of bacteria after a urinary tract infection should be a common practice for primary care physicians.

Incidence of Bladder Cancer in Recurrent UTIs

Mdm W’s presentation was not typical of bladder cancer. She did not present with gross haematuria, a complicated urinary tract infection, or have risk factors suggestive of malignancy. The decision for referral to urology was due to the concern that she had a persistent urinary tract infection with the same organism being cultured 4 times from her urine without interval documented clearance, with concern of underlying undiagnosed urinary tract abnormality. In a primary care based study in the United Kingdom, 17 percent of bladder cancer patients presented with UTI and 9 percent with dysuria, but the symptoms themselves might have an overall low positive predictive value for bladder malignancy (0.6% and 0.3%, respectively).³ The finding of bladder cancer appears fortuitous in this case.

A bidirectional cause-effect relationship between bladder cancer and malignancies have been proposed. Mechanisms include increased exposure of the bladder to urinary carcinogens during a period of urinary retention and stasis.^{4,5} In addition, bacterial flora in the urine may contribute to the

production of nitrites that are converted to carcinogenic nitrosamines.^{6,7,8} Bladder cancer can also cause a functional decrease in the bladder capacity, detrusor over-activity, invasion of the trigone, or obstruction of the bladder neck or urethra.⁹ This results in lower urinary tract symptoms and, notably, the complex of dysuria, frequency, and urgency is highly suggestive of bladder carcinoma-in-situ.¹⁰

Prognostication of the Bladder Tumours that Present with UTIs

A retrospective cohort study of 12,195 Americans under Medicare identified an increased risk of mortality from bladder cancer in women presenting with urinary tract infection (hazard ratio 1.37, 95% confidence interval 1.10-1.71) compared with women with haematuria.¹¹ It also found the mean time to bladder cancer diagnosis was 72.2 days in women versus 58.9 days in men ($P < 0.001$). This is consistent with a study in 1994 that UTIs increased the risk of an advanced bladder cancer stage on diagnosis.¹²

CONCLUSIONS

Urinary tract infections need to be followed up to resolution. The gaps in this case illustrate why this was not done. Structural abnormality needs to be excluded. In this case it was not anatomical abnormality that was uncovered. It was a cancer of the bladder which was fortunately still localised.

REFERENCES

1. Dason S, Dason JT, Kapoor A. Guidelines for the diagnosis and management of recurrent urinary tract infection in women. *Can Urol Assoc J*. 2011;5:316–22.
2. Franco AV. Recurrent urinary tract infections. *Best Pract Res Clin Obstet Gynaecol*. 2005;19:861–73.
3. Shephard EA, Stapley S, Neal RD, Rose P, Walter FM, Hamilton WT. Clinical features of bladder cancer in primary care. *Br J Gen Pract*. 2012; 62:e598–604. (Erratum in *Br J Gen Pract*. 2014 Mar;64:126.)
4. Merk FB, Pauli BU, Jacobs JB, Alroy J, Friedell GH, Weinstein RS. Malignant transformation of urinary bladder in humans and in N-[4-(5-Nitro-2-furyl)-2-thiazolyl] formamide-exposed Fischer rats: ultrastructure of the major components of the permeability barrier. *Cancer Res*. 1977;37:2843–53.
5. Kantor AF, Hartge P, Hoover RN, Narayana AS, Sullivan JW, Fraumeni JF Jr. Urinary tract infection and risk of bladder cancer. *Am J Epidemiol*. 1984;119:510–5.
6. Hicks RM, Walters CL, Elsebai I, Aasser AB, Merzabani ME, Gough TA. Demonstration of nitrosamines in human urine: preliminary observations on a possible etiology for bladder cancer in association with chronic urinary tract infections. *Proc Roy Soc Med*. 1977;70:413–7.
7. Radomski JL, Greenwald D, Hearn WL, Block NL, Woods FM. Nitrosamine formation in bladder infections and its role in the etiology of bladder cancer. *J Urol*. 1978;120:48–50.
8. Johansson S, Wahlqvist L. Tumors of urinary bladder and ureter associated with abuse of phenacetin-containing analgesics. *Acta Path Microbiol Scand*. 1977;85:768–74.
9. González EV, de la Fuente MP, Díaz EG. Urinary incontinence as a presenting symptom of bladder cancer. *Obstet Gynecol Cases Rev*. 2016;3:080.
10. Farrow GM, Utz DC, Rife CC, Greene LF. Clinical observations on sixty-nine cases of in situ carcinoma of the urinary bladder. *Cancer Res*. 1977;37:2794–8.
11. Richards KA, Ham S, Cohn JA, Steinberg GD. Urinary tract infection-like symptom is associated with worse bladder cancer outcomes in the Medicare population: implications for sex disparities. *Int J Urol*. 2016;23:42–7. DOI: 10.1111/iju.12959.
12. Sturgeon SR, Hartge P, Silverman DT, Kantor AF, Linehan WM, Lynch C, et al. Associations between bladder cancer risk factors and tumor stage and grade at diagnosis. *Epidemiology*. 1994;5:218–25.