

THE ROLE OF POCUS IN COMMUNITY AND HOME CARE

Dr Luo Yang, Ms Tan Hui Juan Jennifer, Dr Lee Shaowen Joshua, Dr Tan Kok Heng Adrian

ABSTRACT

Due to its portability and accessibility, point-of-care ultrasound (POCUS) has significant potential for application in community and home care settings. We conducted a literature review on the use of POCUS in these settings, highlighting its role in screening, diagnosis, therapeutic monitoring, and assistance with bedside procedures. Key applications include assessing fluid status, monitoring cardiac failure, confirming nasogastric tube placement, and facilitating paracentesis in patients with ascites.

Keywords: POCUS, community, home care

SFP2025; 51(4): 45-48

INTRODUCTION

Point-of-care ultrasound (POCUS) enables real-time imaging directly at the patient's bedside. Unlike other imaging methods, such as X-rays and CT scans, POCUS is cost-effective, portable, and free from ionising radiation.¹ With the increasing emphasis on healthcare delivery in community and home settings,² POCUS has significant potential to improve access for patients facing mobility challenges or barriers to hospital-based imaging. In this article, we review the current literature on the use of POCUS in the community, with a particular focus on its application in home care environments.

DR LUO YANG, MBBS
Resident (Family Medicine)
National Healthcare Group

MS TAN HUI JUAN JENNIFER
Medical Student
National University of Singapore

DR LEE SHAOWEN JOSHUA, MBBS, MRCP (UK),
MMED (INT MED) GRAD DIP (PALL MED)
Associate Consultant
Department of Continuing and Community Care
Tan Tock Seng Hospital

DR TAN KOK HENG ADRIAN
Senior Consultant
Department of Continuing and Community Care
Tan Tock Seng Hospital

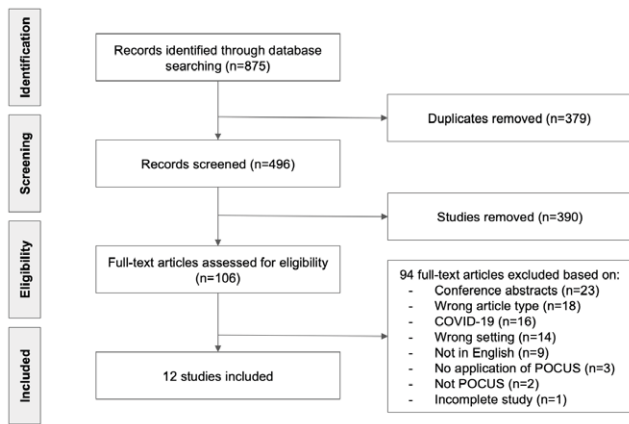
LITERATURE SEARCH

A comprehensive search was conducted in April 2024 across the Cochrane Library, CINAHL, Embase, Medline, PubMed, and Web of Science databases, using controlled vocabulary and free-text terms related to POCUS and community care (refer to **Table I**). The search, performed by a senior librarian, yielded 875 articles. After removing duplicates, 496 articles were screened by two authors (JHJT, JSL), with disputes resolved by a third author (AKHT). Inclusion criteria encompassed using POCUS at home or in a home care setting, and its application for diagnosis, monitoring, follow-up, procedures, or condition management. Exclusion criteria included its use in obstetric populations, individuals under 16 years of age, educational purposes, and resuscitation settings. Following this, seven studies and five case series or reports were included in this review (refer to **Figure 1**).

Table I: Search Strategy

#1: ("point of care systems"[MeSH:NoExp]) AND ("ultrasonography"[MeSH Terms])
#2: ("pointofcare"[Title/Abstract] OR point-of-care[Title/Abstract] OR wireless[Title/Abstract] OR bedside[Title/Abstract] OR "hand held"[Title/Abstract] OR hand-held[Title/Abstract] OR portable[Title/Abstract]) AND (ultrasound*[Title/Abstract] OR ultrasonography[Title/Abstract])
#3: POCUS[Title/Abstract]
#4: #1 OR #2 OR #3
#5: ((((((“residential facilities”[MeSH:NoExp]) OR (“assisted living facilities”[MeSH:NoExp])) OR (“homes for the aged”[MeSH:NoExp])) OR (“hospices”[MeSH:NoExp])) OR (“home care services”[MeSH:NoExp])) OR (“home care services, hospital based”[MeSH:NoExp])) OR (“home nursing”[MeSH:NoExp]))
#6: home[Title/Abstract] OR homes[Title/Abstract] OR hospice[Title/Abstract] OR hospices[Title/Abstract]
#7: #5 OR #6
#8: #4 AND #7

Figure I: Preferred Reporting Items for Systematic reviews and Meta-Analyses (PRISMA) flow chart



THE USE OF POCUS IN COMMUNITY CARE

POCUS serves multiple roles in community settings, offering versatile applications such as screening for various conditions, diagnostic support, therapeutic monitoring, and assistance with interventional procedures. The literature highlights its use by specialists (e.g., gastroenterologists and geriatricians), primary care physicians, and community nurses. These applications are summarised in **Table II**.

Table II:

Author	Country	N	Setting	Role of POCUS	Conditions	Operator
Arpaia (2011)	Italy	221	Home care Institutions	Screening	Deep vein thrombosis	Angiologist
Arya (2022)	Canada	89	Clinic Home care Institutions Hospital	Diagnostic, Procedural	Diagnosis: ascites, pleural effusion, pneumonia, pneumothorax, heart failure, bowel obstruction Procedures: paracentesis, thoracentesis	Palliative care physician
Bonnel (2019)*	United States	16	Home care	Monitoring	Intravascular status, dyspnoea/hypoxia, acute retention of urine	Geriatrician
Landers (2014)	New Zealand	32	Community	Diagnostic, Procedural	Diagnostic: ascites Procedural: paracentesis	Palliative care physician
Liao (2020)	Taiwan	132	Home care, institution	Screening, Diagnostic	Intra-abdominal organs, peritoneal cavity, pleural space	Gastroenterologist
Mak (2020)	Hong Kong	68	Community	Procedural	NGT placement confirmation	Nurses
Mariani (2009)*	United States	2	Home care	Diagnostic, Procedural	Diagnostic: ascites Procedural: paracentesis	Emergency physician
Matsumoto (2020)*	Japan	1	Home care	Monitoring	Constipation	Nurses (Palliative)
Ota (2020)*	United States	33	Home care	Procedural	Procedural: paracentesis	Primary care physician
Santos (2019)*	--	1	Home care	Diagnostic	Heart failure	Primary care physician
Tromp (2023)	Tunisia	94	Home care	Screening	Heart failure	Nurses
Zisis (2023)	Australia	122	Home care	Monitoring	Heart failure	Nurses

A TOOL FOR SCREENING AND DIAGNOSIS

POCUS demonstrates significant potential in the diagnosis and screening of various conditions. In a study by Arpaia, POCUS was used to screen for deep vein thrombosis (DVT) in immobilised patients through bilateral lower limb compression ultrasonography, identifying an 18 percent prevalence (95% CI 13-24%) of asymptomatic proximal DVT in this population.³

More recently, Tromp explored the use of AI-augmented POCUS by community nurses for heart failure screening.⁴ Measurements of left ventricular ejection fraction and left atrial volume index were performed in home care patients. The study compared the sensitivity of POCUS-detected heart failure with N-terminal pro-B-type natriuretic peptide (NT-proBNP) serum testing, benchmarking both against clinic-based transthoracic echocardiography. AI-POCUS demonstrated a high sensitivity of 92 percent (95% CI 62-99) for heart failure detection, compared to 87 percent (95% CI 60-98) for NT-proBNP.

Other notable applications of POCUS reported in the literature include its use in screening and diagnosing intra-abdominal pathologies involving the hepatobiliary system, kidneys, and spleen, as described by Liao.⁵ Several articles also highlighted its value in identifying ascites and pleural effusions, particularly in palliative care settings.⁶⁻⁹

SUPPORTING CLINICAL DECISIONS

Bonnel reported a case series on the use of POCUS in home care by trained geriatricians.¹⁰ In the article, POCUS was used to assess fluid or hydration status, evaluate the causes of shortness of breath, and determine bladder volume in cases of urinary retention. The application of POCUS-facilitated clinical decision-making, including diuretic titration and trials to discontinue catheters.

Similarly, Zisis investigated the role of POCUS among a cohort of nurses in Australia for triaging heart failure patients who might require escalated care.¹¹ By detecting B-lines on lung ultrasound, POCUS provided an estimate of fluid status, aiding in medication titration decisions and identifying patients who needed more frequent monitoring.

In a case report, Matsumoto discussed the use of POCUS in the assessment and management of constipation in a palliative care patient.¹² POCUS was instrumental in identifying the level of fecal obstruction, enabling targeted interventions to alleviate symptoms.

ASSISTING BEDSIDE PROCEDURES

In addition to assessing ascites, POCUS can assist in performing paracentesis for symptom relief. Ota described a case series in which a trained primary care physician used POCUS guidance to perform home-based paracentesis, effectively alleviating ascitic symptoms in palliative care patients.⁹

Mak conducted a study on the use of POCUS by community nurses for assessing nasogastric tube (NGT) placement.¹³ This method was compared to the pH test or X-ray. NGT placement was directly visualised using POCUS, achieving a high sensitivity of 92.45 percent (95% CI 83.20-97.40%). If visualisation was not possible, air was introduced through the NGT to create a “fogging” effect, confirming placement with a sensitivity of 95.45 percent (95% CI 87.29-99.05%). Both methods demonstrated a high specificity of 100 percent.

DISCUSSIONS

POCUS offers significant advantages for home care patients to improve clinical outcomes. Its portability allows for seamless integration into home visits, enabling healthcare providers to perform real-time assessments and address clinical questions promptly. For patients with limited mobility, POCUS eliminates the need for immediate hospital visits, serving as an effective triaging tool and helping to reduce unnecessary hospital visits.

With POCUS guidance, clinicians can perform targeted therapeutic interventions with enhanced precision and safety. Besides the placement of drainage catheters, POCUS helps with the visualisation of target sites for the delivery of therapeutic agents. Some applications include nerve block procedures for pain control in palliative patients and delivery of botulinum toxins to reduce salivary flow in drooling for patients with end-stage neuromuscular diseases described in one literature.¹⁴

While POCUS holds significant promise in community practice, it is important to acknowledge the challenges associated with its use to ensure its appropriate application. One primary consideration is the operator dependency inherent in ultrasound imaging. Adequate training and proficiency are essential for effective use. Healthcare institutions offering POCUS in home care should implement structured training programmes and conduct regular competency assessments for operators.

As POCUS can serve as a valuable screening tool, careful consideration must be given to interpreting its findings and determining the appropriate next steps. Overdiagnosis may lead to unnecessary evaluations and interventions, potentially causing patient anxiety. To mitigate this, clinicians should use POCUS with clearly defined clinical questions in mind, considering the overall clinical picture and the patient’s goals of care.

To further enhance its usability, especially for less-experienced users, the integration of artificial intelligence (AI) can play a crucial role in assisting with result interpretation, calculating clinical measurements, reducing variability, and improving diagnostic accuracy. One study demonstrated the use of AI-integrated POCUS to calculate left ventricular ejection fraction, allowing nurses to perform accurate assessments after completing a single-day training programme.⁴ While other applications of AI in POCUS have been reported in

inpatient settings, further research is essential to validate AI-generated results before large-scale implementation.¹⁵

CONCLUSION

POCUS is a powerful tool with numerous potential applications in community and home care settings. Current literature highlights only a fraction of its capabilities, with many applications still underexplored. There is considerable potential for future research to expand the use of POCUS in home care, as well as to develop training programmes for its application and integrate AI to enhance diagnostic support.

ACKNOWLEDGEMENT

We would like to thank Ms Yasmin Lynda Munro, Senior Medical Librarian at the NTU Lee Kong Chian School of Medicine Medical Library, for conducting the literature search.

REFERENCES

1. National Institute of Biomedical Imaging and Bioengineering. Ultrasound. National Institute of Biomedical Imaging and Bioengineering. 2023 [cited 2024 Nov 30]. Available from: <https://www.nibib.nih.gov/science-education/science-topics/ultrasound>
2. Thio SM, Tan AKH. Community Centre-based Care services for a Frailty-Friendly Community in Singapore. *Singap Fam Physician*. 2018 Oct 1;44(5):34-9. <https://dx.doi.org/10.33591/44.5.o1>.
3. Arpaia G, Ambrogi F, Penza M, et al. Risk of Venous Thromboembolism in Patients Nursed at Home or in Long-Term Care Residential Facilities. *Int J Vasc Med*. 2011;2011:305027. doi: 10.1155/2011/305027. Epub 2011 Jun 13. PMID: 21748017; PMCID: PMC3124858.
4. Tromp J, Sarra C, Nidhal B, et al. Nurse-led home-based detection of cardiac dysfunction by ultrasound: results of the CUMIN pilot study. *Eur Heart J Digit Health*. 2023 Dec 12;5(2):163-169. doi: 10.1093/ehjdh/zta079. PMID: 38505488; PMCID: PMC10944680.
5. Liao MK, Lin CL, Wu TY, et al. Portable Abdominal Sonographic Findings and Characteristics of Service Users in the Community. *Aging Med Healthc*. 2020 Dec 31;11:116-22. <https://dx.doi.org/10.33879/AMH.114.2020.01002>.
6. Arya A, Davey R, Sharma A, et al. Utilization of Point-of-Care Ultrasound in a Specialist Palliative Care Team Across Multiple Care Settings: A Retrospective Chart Review. *Palliat Med Rep*. 2022 Oct 21;3(1):229-234. doi: 10.1089/pmr.2021.0067. PMID: 36341470; PMCID: PMC9629911.
7. Landers A, Ryan B. The use of bedside ultrasound and community-based paracentesis in a palliative care service. *J Prim Health Care*. 2014 Jun 1;6(2):148-51. PMID: 24892133.
8. Mariani PJ, Setla JA. Palliative Ultrasound for Home Care Hospice Patients. *Acad Emerg Med*. 2010 Mar;17(3):293-6. doi: 10.1111/j.1553-2712.2009.00678.x. PMID: 20370762.
9. Ota KS, Schultz N, Segaline NA. Palliative Paracentesis in the Home Setting: A Case Series. *Am J Hosp Palliat Care*. 2021 Aug;38(8):1042-1045. doi: 10.1177/1049909120963075. Epub 2020 Sep 30. PMID: 32996326.
10. Bonnel AR, Baston CM, Wallace P, Panebianco N, Kinosian B. Using Point-of-Care Ultrasound on Home Visits: The Home-Oriented Ultrasound Examination (HOUSE). *J Am Geriatr Soc*. 2019 Dec;67(12):2662-2663. doi: 10.1111/jgs.16188. Epub 2019 Oct 6. PMID: 31587264.
11. Zisis G, Carrington MJ, Yang Y, et al. Use of Imaging-guided Decongestion for Reducing Heart Failure Readmission and Death in High-risk Patients: A Multi-site Randomized Trial of a Nurse-led Strategy at the Point of Care. *J Card Fail*. 2024 Apr 1;30(4):624-9. doi: 10.1016/j.cardfail.2023.12.007. Epub 2023 Dec 25. PMID: 38151092.
12. Matsumoto M, Yabunaka K, Yoshida M, et al. Improvement of Constipation Symptoms in an Older Adult Patient by Defecation Care Based on Using a Handheld Ultrasound Device in Home Care Settings: A Case Report. *J Wound Ostomy Continence Nurs*. 2020 Jan/Feb;47(1):75-78. doi: 10.1097/WON.0000000000000610. PMID: 31929449.
13. Mak MY, Tam G. Ultrasonography for nasogastric tube placement verification: an additional reference. *Br J Community Nurs*. 2020 Jul 2;25(7):328-34. doi: 10.12968/bjcn.2020.25.7.328. PMID: 32614666.
14. Breheret R, Bizon A, Jeurfroy C, Laccourreye L. Ultrasound-guided botulinum toxin injections for treatment of drooling. *Eur Ann Otorhinolaryngol Head Neck Dis*. 2011 Nov 1;128(5):224-9. doi: 10.1016/j.anorl.2010.12.010. Epub 2011 May 19. PMID: 21600865.
15. Mika S, Gola W, Gil-Mika M, Wilk M, Misiotek H. Overview of artificial intelligence in point-of-care ultrasound. *New horizons for respiratory system diagnoses. Anaesthesiol Intensive Ther*. 2024;56(1):1-8. doi: 10.5114/ait.2024.136784. PMID: 38741438; PMCID: PMC11022635.